

TAPP – THE LOGIC OF HERNIA REPAIR

Jan F. Kukleta

Zurich - SUISSE

The presented article has three clear objectives : To highlight the advantages and disadvantages of endoscopic hernia repair in general, to describe the technique TAPP in detail and to try to clarify, why the TAPP repair should become the logical part of surgical training.

The groin hernia repair is one of the most frequent surgical procedures performed today. The quality of patient's outcome per se, its socioeconomic impact, the changing pattern of living, fast social pace, professional pressure and the technology driven evolution of surgical therapies have deeply influenced the hernia surgery. The scientific achievements in the field of collagen have changed our understanding of an entity called "hernia disease" and the surgical community is progressively getting aware of the importance of hernia repair related consequences.

The progress of laparoscopic techniques demonstrated impressively in the last 20 years the advantages of minimal invasive surgery. MIS became a modern therapeutic concept. It applied well to the most known abdominal procedures leading so to the popular comment : "In laparoscopy just do like in open surgery". This did not fit to endoscopic hernia solutions. The repair philosophy has changed from sutured to tension-free, the approach and anatomy were completely new (for the most) and the procedure required a prosthetic mesh as an indispensable part of the tension-free repair.

After overcoming the pioneer gestures like Ger's herniostat, stuffing the indirect sac with polypropylene rolls or transecting the hernia sac with Endo-GIA, finally two endoscopic techniques have established to stay : TAPP and TEP. Despite of a clear and relatively simple operative strategy the learning curve showed to be longer and more difficult as initially expected.

TAPP and TEP made out of a "simple and easy resident teaching operation" a complex enigma, which was first to be defeated rather than adopted.

No wonder the penetration of endoscopic groin hernia repair within the surgical community was slow. The new alternatives of a hernia repair raised the attention not only of surgeons, but of patients too. The expectation of faster recovery and more durable repair has been spread by popular print media and internet faster than among professionals.

MOTS CLÉS : Endoscopic hernia repair, TAPP, TEP, Surgical training.

□ ANALYSIS

Status quo

➤ **Fact 1. – Recurrence rate.**

Both in the open and in the laparoscopic repair the mesh gained the acceptance step by step due to clear improvement of the recurrence rate. This facilitated the shift from Shouldice technique to Lichtenstein repair. As the later one became more and more popular for being anatomically easier, the acceptance of mesh in general slowly improved [1, 2, 3].

The recurrence rate of endoscopic mesh repairs in recurrent hernia can be nearly as low as in primary repairs. This is the reason for recommendation of endoscopic techniques in recurrent disease [1, 4].

➤ **Fact 2. – Infection rate.**

Over the years it could be demonstrated that the infection rate in open mesh repairs is of concern, meanwhile in endoscopic repairs infections are very rare, if not inexistent [6, 33].

➤ **Fact 3. – Postoperative acute pain.**

The classical three trocar procedure causes minimal discomfort in the operated groin (the patient very often doesn't recognize whether he was operated uni- or bilaterally) and a very well tolerated low VAS-graded pain at the trocar incision site [6]. Trivial analgesia is supported by intraoperative wound infiltration with naropin.

➤ **Fact 4. – Chronic pain.**

The incidence of chronic pain after anterior approach in hernia repair is evidently higher than in endoscopic tech-

niques [5, 8]. In order to resolve the problem of elevated risk of chronic pain in open mesh repair, the nerve preserving techniques vs. primary neurotomy/neurectomy are under evaluation and became a standard topic of the most hernia congresses today [7]. Meanwhile the endoscopic repairs appreciate their renaissance, being finally recognized to have the lowest risk for acute and chronic pain.

➤ **Fact 5. – Recovery, return to normal activities**

Despite the need of general anaesthesia for endoscopic groin hernia repair TAPP and TEP can be performed as day surgery or one night stay. The disability and off-work period are shorter than in open repairs.

➤ **Fact 6. – Reinforcement of the whole myopectineal orifice (MPO).**

The endoscopic repairs enable deployment of much bigger mesh size, than in open repair (with the exception of Stoppa repair). The prosthetic material doesn't plug the hole or patch the defect, but overlaps the whole myopectineal orifice [4, 8, 21]. The retromuscular flat mesh placement of at least 10 x 15 cm is physically logical and more efficient than trans-inguinal (TIPP, PHS, UHS, plug) or praemuscular (plug & patch, Lichtenstein, etc.) mesh deployment. The meshes in open repair are smaller; the overlap is limited or none (e.g. Lichtenstein and femoral hernia).

➤ **Fact 7. – Cost.**

Direct cost.

Instruments: The early experience of endoscopic repair was marked by multiple use of disposable or single use instruments (trocars, balloons, staplers, etc.). Reusable instruments, suturing, glues and the trend to non-fixation in adequate constellations lowered substantially the cost difference.

Operation time: The difference in average operating times is small and often a result of learning curve or teaching procedure.

Anaesthesia: The endoscopic repair is performed under general anaesthesia, which certainly is a cost factor. But even for open repair under local anaesthesia with sedation (LA + S) the anaesthesiology – personnel must be present. The preference of doctors and patients shows, that the often mentioned great advantage of LA + S in open repair was in the most European countries seldom used and its little popularity is on further decline.

Indirect cost.

The earlier return to work, smaller loss of productivity and less postoperative medical care after endoscopic repairs can help to compensate the overall cost, if consequently set into reality [9, 10]. Due to different health care systems, different reimbursement strategies, various hospital politics, cultural and demographic differences it is nearly impossible to express the difference in serious and convincing numbers.

There is a significant paper of Stylopoulos et al. [10] evaluating over 1.5 million hernia repairs, demonstrating that endoscopic hernia repair may be cheaper than the Lichtenstein repair if overall cost is considered.

➤ **Fact 8. – Learning and teaching.**

In contrary to the open mesh repair the endoscopic groin hernia repair is to be understood as an advanced procedure, at least until the basic laparoscopic skills are acquired and routinely performed. As in open repair the knowledge of local anatomy is "conditio sine qua non". Endoscopic hernia repair requires many surgical gestures and tasks necessary for other endoscopic intra- and retroperitoneal procedures: good patient selection, knowledge of the procedure, establishing pneumoperitoneum, trocar placement strategy, clean dissection technique, controlled haemostasis and preservation of the parietal peritoneum, bimanual handling of mesh or suturing.

Teaching surgery inherits a big load of responsibility. There is no doubt of the value of MIS contribution to surgical therapy per se. Preparation of surgical trainees for their professional future has to include the minimal invasive laparoscopic techniques on basic and advanced level. The frequency of hernia surgery offers a chance to build-up a well structured standardized educational programme for both the teachers and the trainees.

➤ **Fact 9. – Morbidity and complications.**

In the first years after introduction of endoscopic hernia repair there were some major and quite a few minor complications reported [11]. Insufficient knowledge of anatomy, limited working space, lack of necessary skills, inappropriate instrumentation and simply inexperience in minimal invasive surgery with its well known limitations led to numerous adverse outcomes. These deficits were then summarized under so called "early learning curve". Those outcomes have nowadays a historical character and symbolize only a difficult birth of a new technique.

Today's understanding of a (trainee's) learning curve has to be different. Nobody has to invent the wheel by himself: it has been invented already and there are enough experienced surgeons to give you a hand. There is no apology for using too small meshes within your own learning curve today, it is negligence. There is enough knowledge and experience published to get informed.

There are access- and procedure-related complications, besides the non-specific ones. Neither the open Hasson's technique to establish pneumoperitoneum, nor the Verres needle with or without optical trocar can prevent vascular or intestinal injuries 100 % [12, 13, 14, 15, 16]. There are clear rules how to handle and how to proceed in order to prevent preventable complications. My personal opinion is that the published complications addressed more often to TAPP (vs TEP) are reflecting the very early learning curve [11].

> *Fact 10. – TAPP vs. TEP*

The choice of approach to the laparoscopic repair of inguinal hernia is still controversial.

There are very few comparative studies of TAPP vs. TEP, both have advantages and disadvantages, the importance of their relative merits and risks is unclear. There is insufficient data to allow conclusions to be drawn about the relative effectiveness of TEP compared with TAPP [17].

Both approaches have the same task to accomplish: to extend a 10 x 15 cm or bigger mesh in the praeritoneal space, that covers the same determined region.

TEP enters the retromuscular layer infra-umbilically under direct vision and then slides distally towards the symphysis developing the praeritoneal space step by step. The working space is limited until the hernias are reduced and the lateral caudal peritoneum is mobilized above the psoas muscle. This makes the dissection and the mesh placement more difficult. Therefore it seems that the learning curve for TEP is even more difficult than for TAPP.

TAPP enters the abdominal cavity first and opens the praeritoneal space above the hernia defects. The biggest advantage is the overall view of ipsi-/and contralateral side and much greater working space, the drawback is the necessity of peritoneal closure, which is time-consuming and technically difficult. At the same time it offers a chance to perfect the skills in endoscopic suturing, that must be acquired somewhere somehow anyway to complete the repertoire of a laparoscopic surgeon.

□ TECHNIQUE OF TAPP

> *Establishing pneumoperitoneum*

Both Hasson's open technique as well as the Verres needle, insufflation and trocar insertion with or without optical aid present a minimal, but existing potential risk of intraabdominal injury. This step requires therefore major attention considering patient's history, previous incisions, BMI, proper technique, aspiration- and drop-tests, etc. Lifting the abdominal wall increases the distance of the tip and the retroperitoneal vessels, but does not protect loops adherent to the abdominal wall. Insertion of the first (additional) trocar in safer localisation and completing the habitual placement under visual control might be helpful. CO₂ insufflation, working intraabdominal pressure is 9 – 12 mm Hg.

> *Trocar placement*

The first 10 mm trocar (T1) is placed in the sub-umbilical fold. 30° Endoscope is used. The right-handed surgeon will place his T2 5 mm (for grasping) left pararectally and T3 10-12 mm right pararectally (scissors, dissector, mesh, haemostatic devices, tackers, suture, etc.) at the same level as T1. The left-handed will prefer to switch T2 and T3. The trocars should be conical, dilating and not cutting. The incidence of trocar site haemorrhage or trocar hernias is much

lower in the first group [18]. The operating surgeon stands at the patient's breast level on the contralateral side of the hernia and changes the sides in case of bilaterality. My personal preference is to stand at the right side for both left and right TAPP repairs.

> *Exploration*

First both groins are explored, than all four quadrants should be explored too. In 10-15 % of unilateral hernias diagnosed preoperatively a contralateral hernia can be found at the time of surgery [19]. The patient should be informed of this and simultaneous repair should be performed. Interestingly in TAPP the incidence of bilateral hernias is lower than in TEP. It seems that the decision to explore the contralateral side in TEP is little less accurate.

> *Peritoneal dissection*

The peritoneum is incised from anterior upper iliac spine above the inner ring up to medial umbilical ligament. The later does not need to be divided. The correct plane of dissection lies between the inner and outer leaf of peritoneum, preserving so the endo-abdominal- and later the spermatic

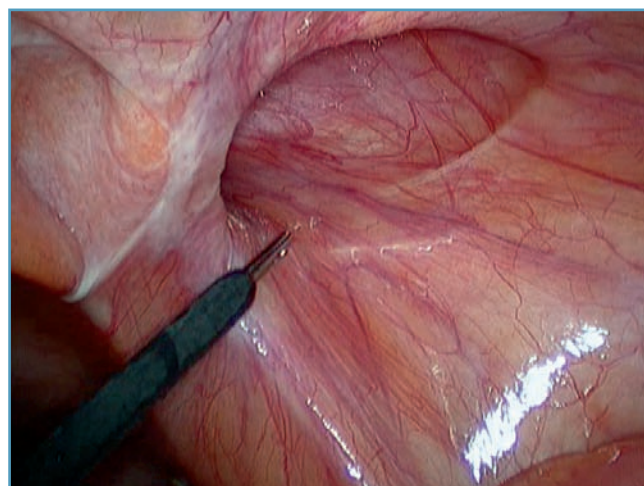


Fig. N° 1

Right indirect hernia

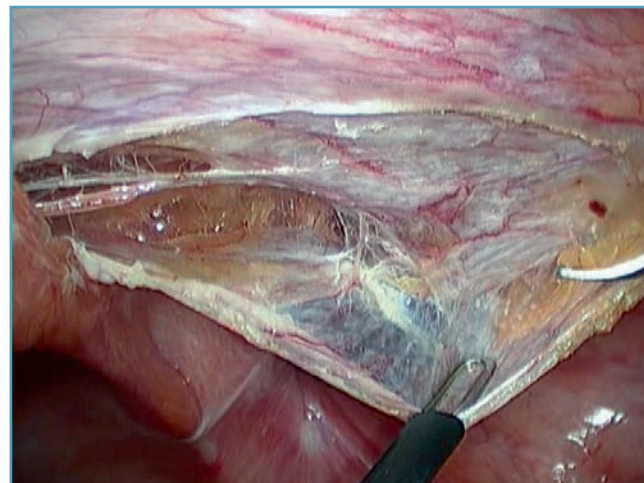


Fig. N° 2

The two peritoneal layers

fascia too. This plane is nearly avascular and the intact fascia protects the genitofemoral and lateral cutaneous femoral nerves from direct mesh contact [20]. All present hernia sacs are fully retracted (Fig. N°1-5).

In direct hernia the preoperational fat is separated from the transversalis fascia (TF) and retracted. In big hernias the

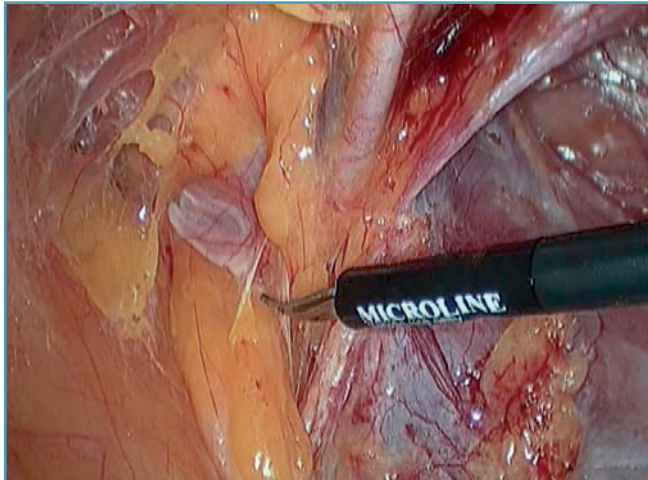


Fig. N° 3 *Everted transversalis fascia, epigastric artery*

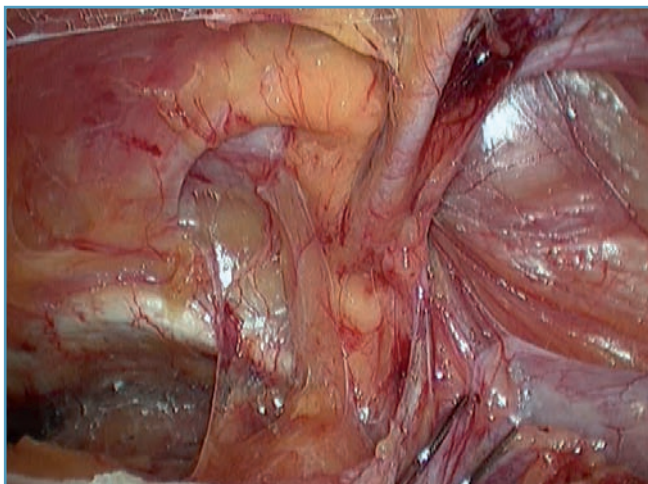


Fig. N° 4 *Dissection of preperitoneal space*

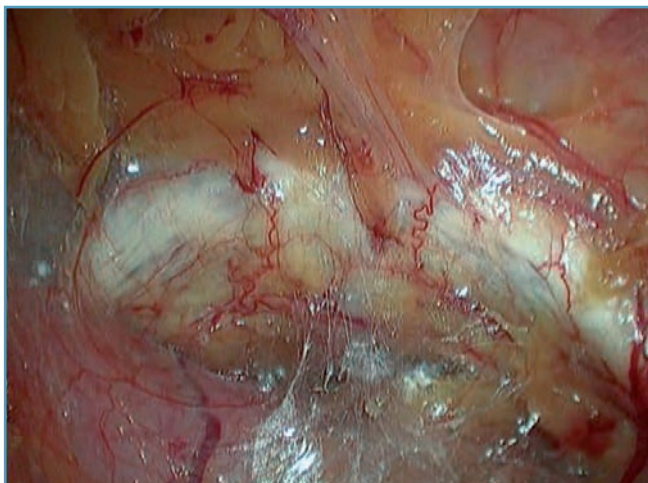


Fig. N° 5 *Symphysis, Cooper's ligament*

TF can be inverted and fixed to Cooper's ligament reducing the risk of postoperative seroma (pseudohernia) [22].

The femoral orifice is checked and prolapsing preoperational fat is carefully extracted. Often after a cautious traction unexpected tissue volume can be pulled out of the femoral canal, freeing the patient from previous symptoms.

The vast majority of indirect hernia sacs can be brought into abdomen and completely reduced. The transection of the sac is only exceptionally necessary, having a risk to develop a "hydrocele" in the distal sac. The inguinal canal is explored and lipomas extracted and resected. Origin of these lipomas is the retroperitoneal fat below the ileopubic tract, laterally of the spermatic vessels. They can become symptomatic even years after a successful mesh repair simply sliding into the enlarged inner ring. Attention is paid to the crossing branches of the ramus femoralis of the genitofemoral nerve.

The landmarks of the dissection extent are medially 1-2 cm beyond symphysis or across the midline, caudally overlapping Cooper's ligament by minimally 2 cm, 3-4 cm over the transversalis arch or the proximal margin of the inner ring, reaching laterally the iliac spine and latero-caudally over psoas muscle.

➤ *Mesh placement and fixation*

Megaporous non absorbable light-weight mesh of 10 x 15 cm size is spread and adapted wrinkle-free to the underlying tissues. The mesh can be fixed by staples, absorbable or non absorbable sutures or tacks, with fibrin or a glue or under convenient conditions left unfixed [23, 24, 25, 26, 27].

My personal preference is Ultrapro®¹ mesh and Glubran-2®² tissue glue for mesh retention. In bigger direct hernias is more rigid mesh material (e.g. Prolene®¹) and absorbable fixation (suture, Permasorb®³ or Absorbatack®⁴) justified. (Fig. N°6-9).

➤ *Peritoneal closure*

In order to prevent a small bowel obstruction and any kind of direct mesh contact with viscera thorough peritoneal closure and eventual closure of a hernia sack orifice (cave inner hernia) must be achieved. The running absorbable suture certainly serves the best (Fig. N°10).

➤ *Trocar incision closure*

The trocar wounds bigger than 5 mm are closed in layers and infiltrated with naropine [28].

➤ *Postoperative care*

No bodily restrictions recommended, sports within 5-7 days. Off work period 3-10 days, depending on age, type of labour and motivation.

¹ *Ethicon Endo-Surgery*

² *Lina Medical*

³ *Bard*

⁴ *Covidien*

DISCUSSION

The endoscopic hernia repair claims to be an imitation of Stoppa's GPRVS (giant praepertoneal reinforcement of visceral sac). This is not completely true. Stoppa in his own comment to this issue reinforced the peritoneum with a

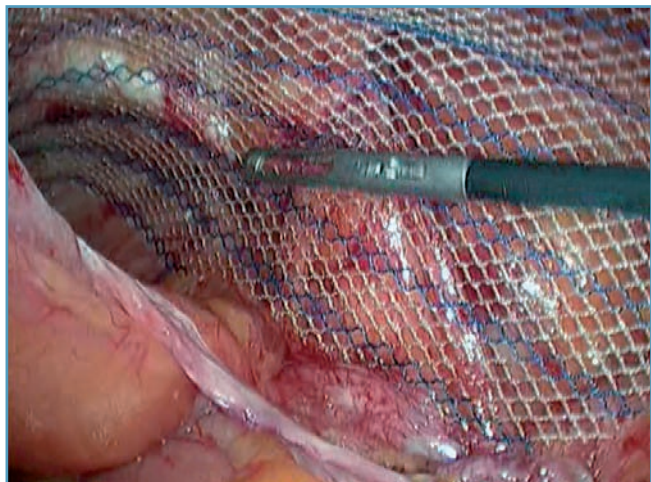


Fig. N° 6 *Wrinkel-free flat megaporous mesh*

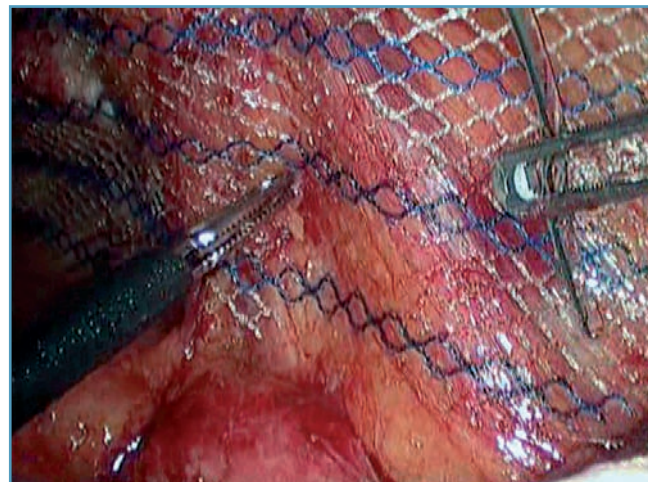


Fig. N° 9 *Fixation of "critical corner" latero-caudally*

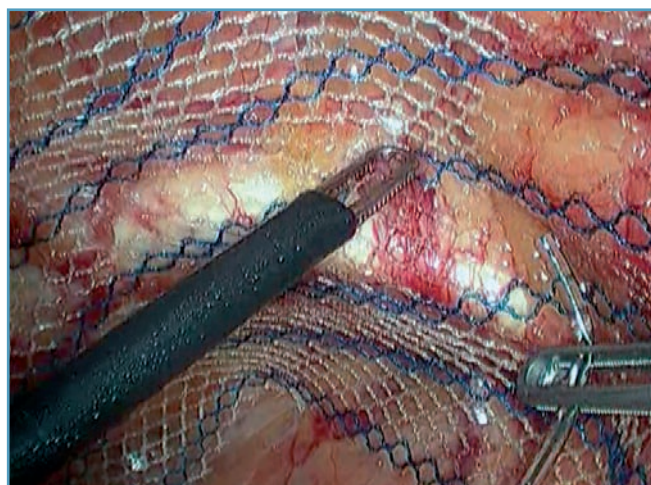


Fig. N° 7 *Well extended mesh is fixed with Glubran-2*

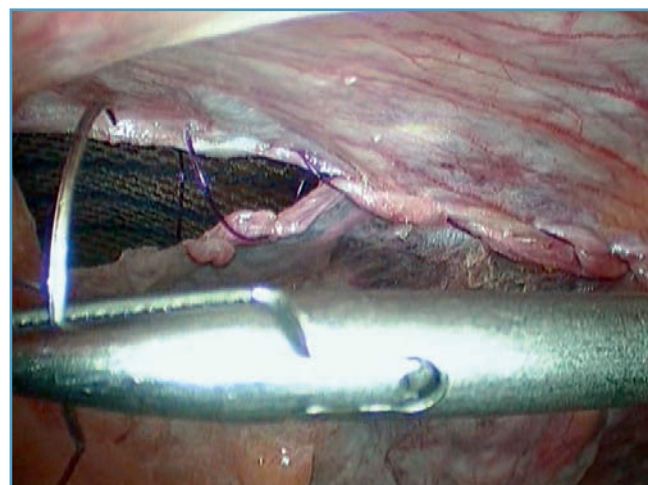


Fig. N° 10 *Peritoneal closure with running PDS suture*

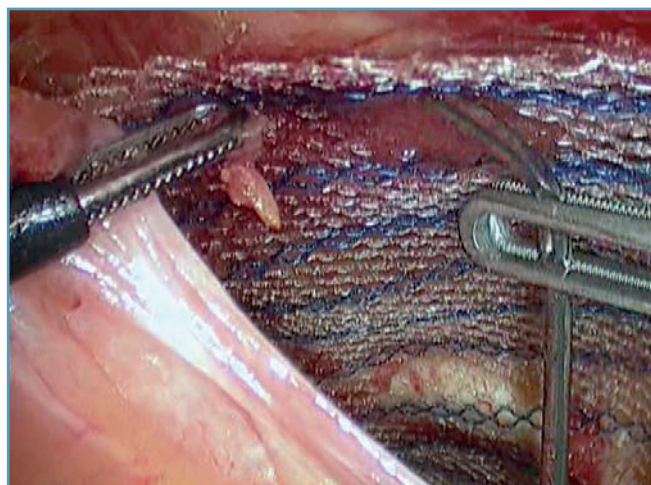


Fig. N° 8 *The cyanoacrylate glue is applied only dropwise*

mesh-scar-complex to make it inextensible and so to prevent a hernia sack formation. Endoscopic surgeons believe to reinforce the abdominal wall and still reduce the scar formation by the use of light-weight meshes. Both rely on Pascal's hydrostatic law. The main force that creates the hernia helps to keep the mesh in place by pressing it to the wall, making

the fixation of adequately sized macroporous mesh in many cases dispensable. There is a visible trend towards non fixation. But there are already reports warning, due to a rising recurrence rate since the implementation of light-weight meshes [24].

Slitting the mesh and wrapping it around the cord structures in order to prevent a dislocation showed to be wrong [4, 29]. Besides being a danger of strangulation, direct injury and unnecessary exposure of vas deferens to inflammatory process and excessive scarring, the reunion of the mesh tails carries the risk of failure.

Stoppa used one bilateral mesh of a big size and did not fix it, whereas the difficulty of endoscopic placement made the meshes in two pieces and smaller, rarely overlapping in the midline. To compensate the size deficit and to prevent

the mesh dislocation a strong penetrating fixation seemed to be necessary (early nineties). Today we know it's not the strength of fixation, but the mesh size and correct placement that keeps the mesh in place supported by the intrabdominal pressure. The macro-/megaporous mesh structure facilitates the speed of tissue in-growth, vascularisation and extent of incorporation.

CONCLUSION

The endoscopic groin hernia repair offers to the patient a very high quality of the achievable outcome. Although there is a quite clear consensus among experts about the technical details, there is a strong need of standardisation of both TAPP and TEP. There are enough examples well documented in the literature how the outcome's quality can deteriorate e.g. with insufficient mesh size or lack of expertise [30, 31].

Standardisation of a procedure is the easiest way how to reproduce the expected result, the easiest way to teach and learn, the best way to eliminate technical errors. It is effective in anticipation of avoidable complications. Standardized procedures appreciate an improvement of performance through experience and assure the delivery of the "Best practice" [32].

In my personal opinion the TAPP is easier to be standardized, which makes the teaching and learning easier. As this technique offers so many laparoscopic elements to be perfected in a very frequent procedure, it should become our ambition to make it to "The teaching operation" to become a logical part of modern surgical curriculum.

Reproduction avec l'accord de la "Revista Portuguesa di Cirurgia", Copyright Sociedade Portuguesa de Cirurgia. Cet article ne peut être publié dans d'autres revues sans l'accord préalable des tenants du Copyright. Article original paru dans la "Revista Portuguesa di Cirurgia 2009 ; (10) : 59-64.

Jan F. Kukleta
Klinik im Park
Hirslanden Zurich - Switzerland

Correspondance
jfkukleta@hispeed.ch

REFERENCES

- 1 - COLLABORATION EH. : Repair of groin hernia with synthetic mesh: meta-analysis of randomized controlled trials. : *Ann. Surg.* 2002 ; 235 : 322-32.
- 2 - COLLABORATION EH. : Laparoscopic compared with open methods of groin hernia repair: systematic review of randomized controlled trials. : *Br. J. Surg.* 2000 ; 87 : 860-7.
- 3 - COLLABORATION EH. : Mesh compared with non-mesh methods of open groin hernia repair: systematic review of randomized controlled trials. : *Br. J. Surg.* 2000 ; 87 : 854-9.
- 4 - LEIBL BJ, SCHMEDT CG, KRAFT K, ULRICH M, BITTNER R. : Recurrence after endoscopic transperitoneal hernia repair (TAPP): causes, reparative techniques, and results of thereoperation. : *J. Am. Coll. Surg.* 2000 Jun ; 190 (6) : 651-5a.
- 5 - BAY-NIELSEN M, NILSSON E, NORDIN P, KEHLET H. : Chronic pain after open mesh and sutured repair of indirect inguinal hernia in young males. Swedish Hernia Data Base the Danish Hernia Data Base. : *Br. J. Surg.* 2004 Oct ; 91 (10) : 1372-6.
- 6 - BITTNER R, SAUERLAND S, SCHMEDT CG. : Comparison of endoscopic techniques vs Shouldice and other open nonmesh techniques for inguinal hernia repair: a meta-analysis of randomized controlled trials. : *Surg. Endosc.* 2005 May ; 19 (5) : 605-15. Epub 2005 Mar 28.
- 7 - DICKINSON KJ, THOMAS M, FAWOLE AS, LYNDON PJ, WHITE CM. : Predicting chronic postoperative pain following laparoscopic inguinal hernia repair. : *Hernia* 2008 Dec. ; 12 (6) : 597-601. Epub 2008 Jul.
- 8 - KONINGER J, REDECKE J, BUTTERS M. : Chronic pain after hernia repair: a randomized trial comparing Shouldice, Lichtenstein and TAPP. : *Langenbecks Arch. Surg.* 2004 ; 389 : 361-5.
- 9 - HEIKKINEN T, HAUKIPURO K, LEPPALA J, HULKKO A. : Total costs of laparoscopic and Lichtenstein inguinal hernia repairs: a randomized prospective study. : *Surg. Laparosc. Endosc.* 1997 Feb ; 7 (1) : 1-5.
- 10 - STYLOPOULOS N, GAZELLE GS, RATTNER DW. : Cost-utility analysis of treatment options for inguinal hernia in 1.513.008 adult patients. : *Surg. Endosc.* 2003 ; 17 : 180-189.
- 11 - KALD A, ANDERBERG B, SMEDH K, KARLSSON M. : TAPP or TEP approach in laparoscopic hernia repair: Results of 491 consecutive herniorrhaphies. : *Surg. Laparosc. Endosc.* 1997 ; 7 (2) : 86-9.
- 12 - CATARCI M, CARLINI M, GENTILESCHI P, SANTORO E. : Major and minor injuries during the creation of pneumoperitoneum: a multicenter study on 12,919 cases. : *Surg. Endosc.* 2001 ; 15 (6) : 566-569.
- 13 - SCHMEDT CG, LEIBL BJ, BITTNER R. : Access-related complications in laparoscopic surgery. Tips and tricks to avoid trocar complications. : *Chirurg.* 2002 ; 73 (8) : 863-876.
- 14 - NEUDECKER J, SAUERLAND S, NEUGEBAUER E, BERGAMASCHI R, BONJER HJ, CUSCHIERI A, FUCHS KH, JACOBI CH, JANSON FW, KOIVUSALO AM, LACY A, MCMAHON MJ, MILLAT B, SCHWENK W. : The EAES clinical practice guideline on the pneumoperitoneum for laparoscopic surgery. : *Surg. Endosc.* 2002 ; 16 (7) : 1121-1143.
- 15 - MERLIN TL, HILLER JE, MADDERN GJ, JAMIESON GG, BROWN AR, KOLBE A. : Systematic review of the safety and effectiveness of methods used to establish pneumoperitoneum in laparoscopic surgery. : *Br. J. Surg.* 2003 ; 90 (6) : 668-679.
- 16 - HASSON HM. : A modified instrument and method for laparoscopy. : *Am. J. Obstet. Gynecol.* 1971 ; 110 (6) : 886-887.
- 17 - MCCORMACK K, WAKE BL, FRASER C, VALE L, PEREZ J, GRANT A. : Transabdominal preperitoneal (TAPP) versus totally extraperitoneal (TEP) laparoscopic techniques for inguinal hernia repair: a systematic review. : *Hernia* (2005) 9 : 109-114.

- 18 - KRAFT K. : Praktische Hinweise zur Vermeidung von Komplikationen und Rezidiven bei der TAPP. Chirurgie der Leistenhernie. : *Minimalinvasive Techniken* 2006 ; 188-204.
- 19 - NOVITSKY YW, HENIFORD BT, LITWIN DE. : Advantages of TAPP in the evaluation and management of inguinal hernias. : *Am. J. Surg.* 2007 Apr; 193 (4) : 466-70.
- 20 - FOELSCHER DJ, LEROY J, JAMALI FR, MARESCAUX J. : Totally extrafascial endoscopic preperitoneal hernia repair: a merger of anatomy and surgery. The exact description to endoscopically dissect the spermatic fascia. : *Hernia* 2000 ; 4 : 223-227.
- 21 - HEIKKINEN T, BRINGMAN S, OHTONEN P, KUNELIUS P, HAUKIPURO K, HULKKO A. : Five-year outcome of laparoscopic and Lichtenstein hernioplasties. : *Surg Endosc* 2004 ; 18 : 518-522.
- 22 - REDDY VM, SUTTON CD, BLOXHAM L, GARCEA G, UBHI SS, ROBERTSON GS. : Laparoscopic repair of direct inguinal hernia: a new technique that reduces the development of postoperative seroma. : *Hernia* 2007 Oct. ; 11 (5) : 393-6. *Epub* 2007 Jun.
- 23 - KAPIRIS SA, BROUGH WA, ROYSTON CMS, O'BOYLE C, SEDMAN PC. : Laparoscopic transabdominal preperitoneal (TAPP) hernia repair. : *Surg. Endosc.* ; 15 ; 972-975.
- 24 - AKOLEKAR D, KUMAR S, KHAN LR, DE BAUX A, NIXON S. : Comparison of recurrence with lightweight composite polypropylene mesh and heavyweight mesh in laparoscopic totally extraperitoneal inguinal hernia repair : an audit of 1,232 repairs. : *Hernia* 2008 ; 12 : 39-43.
- 25 - MORENO-EGEA A, TORRALBA MARTINEZ JA, MORALES CUENCA G, AGUAYO ALBASINI JL. : Randomized clinical trial of fixation vs nonfixation of mesh in total extraperitoneal inguinal hernioplasty. : *Arch. Surg.* 2004 ; 139 (12) : 1376-1379.
- 26 - LOVISETTO F, ZONTA S, ROTA E, MAZZILLI M, BARDONE M, BOTTERO L, FAILLACE G, LONGONI M. : Use of human fibrin glue (Tissucol) versus staples for mesh fixation in laparoscopic transabdominal preperitoneal hernioplasty : a prospective, randomized study. : *Ann. Surg.* 2007 Feb ; 245 (2) : 222-31.
- 27 - TAYLOR C, LAYANI L, LIEW V, GHUSN M, CRAMPTON N, WHITE S. : Laparoscopic inguinal hernia repair without mesh fixation, early results of a large RCT. : *Surg. Endosc.* DOI 10.1007/s00464-007-9510-7.
- 28 - HON SF, POON CM, LEONG HT, TANG YC. : Pre-emptive infiltration of Bupivacaine in laparoscopic total extraperitoneal hernioplasty : a RCT. : *Hernia* DOI 10.1007/s10029-008-0422-9.
- 29 - FELIX EL, HARBERTSON N, VARTANIAN S. : Laparoscopic hernioplasty. Significant complications. : *Surg. Endosc.* 1999 ; 13 : 328-331.
- 30 - EKLUND A, RUDBERG C, LEIJONMARCK CE, RASMUSSEN I, SPANGEN L, WICKBOM G, WINGREN U, MONTGOMERY A. : Recurrent inguinal hernia: randomized multicenter trial comparing laparoscopic and Lichtenstein repair. : *Surg. Endosc.* 2007 Apr; 21 (4) : 634-40.
- 31 - NEUMAYER L ET AL. : Open mesh versus laparoscopic mesh repair of inguinal hernia. : *N. Engl. J. Med.* 2004 ; 350 : 1819-27.
- 32 - LOVISETTO F, ZONTA S, ROTA E, BOTTERO L, FAILLACE G, TURRA G, FANTINI A, LONGONI M. : Laparoscopic TAPP hernia repair: surgical phases and complications. : *Surg. Endosc.* 2007 Apr ; 21 (4) : 646-52. *Epub* 2006 Nov 14.
- 33 - SCHMEDT CG, SAUERLAND S, BITTNER R. : Comparison of endoscopic procedures vs Lichtenstein and other open mesh techniques for inguinal hernia repair: a meta-analysis of randomized controlled trials. : *Surg. Endosc.* 2005 Feb ; 19 (2) : 188-99.